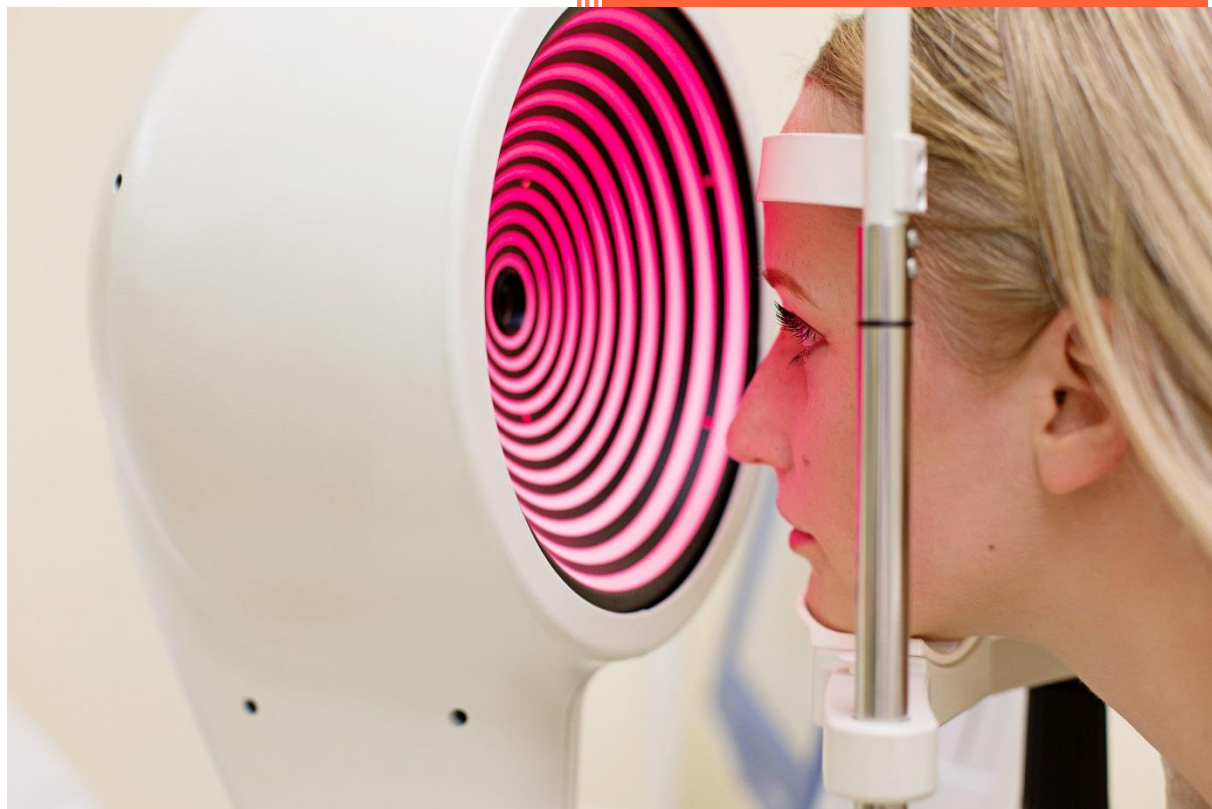


the eye practice

KERATOCONUS – what you need to know



Dr Jim Kokkinakis

Table of Contents

Introduction – What you need to know about keratoconus	3
What causes keratoconus?	4
Hormonal changes	4
Eye rubbing	4
<i>Dry Eye</i>	5
<i>Allergy</i>	5
Collagen disorders.....	5
Genetic factors.....	6
Poor contact lens fit.....	6
Keratoconus diagnosis	7
Diagnostic tests for keratoconus	7
Corneal shape (topography)	7
Corneal thickness	7
Changes to your glasses prescription	7
Keratoconus management.....	8
Spectacle management.....	8
Contact lenses and keratoconus.....	8
Ensure you get the best contact lens fit	9
Types of contact lenses for keratoconus	10
Small diameter RGPs.....	10
Larger diameter RGPs	10
Piggy backs.....	11
Hybrids	11
Sclerals	11
Cutting down on eye-rubbing	12
If you must rub, don't rub your cornea	12
Sort out the itch	13
Cool it down.....	13
More about eye-rubbing and keratoconus.....	14

New treatments for keratoconus	15
What is corneal collagen cross-linking?	15
How does corneal collagen cross-linking work?	16
What are intra-corneal ring segments?	16
Seeing an expert guarantees a better outcome... ..	17
What's in the pipeline?	18
Collagen cross linking combined with laser resurfacing	18
Keraflex	18
Corneal grafts and keratoconus.....	19
Myth 1. A corneal graft is the ultimate treatment for keratoconus.....	19
Myth 2. It will be just like it was before I developed keratoconus... ..	20
Myth 3. Once I get the graft, that's it for life.....	21
Types of corneal graft	21
Full thickness graft (A)	21
Partial thickness (lamellar) graft (B and C).....	21
Case study 1	22
7 Things you should know about keratoconus	23
1. Keratoconus is not a blinding condition	23
2. Keratoconus does not progress forever	24
3. Significantly decreasing eye rubbing is essential!.....	25
4. Not all contact lens solutions are the same.....	25
5. One-step cleaning solutions are not a good idea	26
6. Your optometrist should professionally polish your contact lenses.....	26
7. Keratoconus specialists are far and few between	27
Case study 2	28
About the author	29

Introduction – What you need to know about keratoconus

At *The Eye Practice*, we manage keratoconus from beginning to end. This relatively common disease of the cornea – or front surface of the eye – leads to progressive distortion in vision and can ultimately lead to a corneal graft. Managing keratoconus is our passion and we tackle it from all angles to try and keep you out of needing a corneal graft – often permanently.



After over thirty years delivering eye care, I thought it would be useful to document our extensive experience in dealing with keratoconus. I promise not to bore you with the typical definitions that can be found everywhere. From a layperson's perspective they are of very little use and in fact can be very confusing. Worse still, our experience tells us that many people can become unnecessarily worried about their eye condition. This occurs because the information available on the internet is delivered in a very non-specific manner and most eye care practitioners do not have the experience to deliver accurate information in a customised way to each individual patient.

Keratoconus is an inconvenience, NOT a life sentence.

The Eye Practice optometrists deal with keratoconus every day. What is unfortunate is that the average person seeking care with us will attend their first consultation somewhat distressed after seeing four or five different practitioners. They have been dumped with a whole host of misinformation and usually very little of it has been customised to their individual circumstances. Luckily for you, by reading this document you can finally be put on the right track.

Keratoconus is an inconvenience, NOT a life sentence. As far back as 2005, I wrote a document about the *7 Vital Things you need to know about Keratoconus ... but don't!* This document has been directly downloaded over 30,000 times, world-wide, and, I assume, has been shared around many more times. It has been a great conduit for discussion and over the last ten years I have had many emails from around Australia and around the world asking questions and, just as importantly, asking for direction to a keratoconus specialist near them. I have included an updated version of the *7 Vital Things you need to know about Keratoconus* in this book (see page 20).

Read on to discover the latest information on the causes, diagnosis and management of keratoconus as well as some of the exciting new treatments available.

Jim Kokkinakis

What causes keratoconus?

Keratoconus seems to be related to changing hormonal activity, eye rubbing, collagen disorders and genetics. Progression of the disease is also related to poor contact lens fit.

Hormonal changes

Most cases of keratoconus begin before the age of twenty. There are exceptions to this but the average person that we will see for the first time is a teenager around the age of fifteen.

The average person that we will see for the first time is a teenager around the age of fifteen.

The youngest case I have personally seen was an eight-year-old girl, who had just started puberty. The oldest case of newly-diagnosed keratoconus I have encountered was a forty-four year old man. He had been examined multiple times before the age of forty with perfectly normal corneas. For some unknown reason he developed uncontrolled aggressive eye-rubbing habits, which very quickly destroyed both his corneas. There are cases of older people but their previous history was very vague, so even though they were newly diagnosed, they probably had keratoconus for many years but never had an appropriate consultation.

It is generally accepted that during puberty and other times of hormonal change, there are excessive chemicals (called enzymes) present in the cornea, which cause it to thin. This is why we tend to first diagnose keratoconus during puberty. There have been many case reports of stable keratoconus, which then all of a sudden progress during pregnancy. During this phase of a female's life there is of course another surge of hormonal change.

Eye rubbing

Keratoconus can be induced and certainly made worse by unnecessary eye rubbing. When we see any patient for the first time we support them in every possible way we know, to make sure they understand the implications of eye rubbing with keratoconus and further more to implement strategies to minimise eye rubbing. Two of the biggest culprits in causing eye-rubbing are Dry Eye and Allergy.



Dry Eye

While dry eye doesn't actually cause keratoconus, excessive eye-rubbing is strongly linked to progression of the disease. When eyes are dry, patients often rub aggressively.

Clear instruction to teenagers on regular computer breaks in conjunction with blinking exercises will stimulate the natural lubrication system of the eyes. Where possible, preserved eye drops need to be avoided, as those at risk of developing keratoconus are more likely to be irritated by the preservatives.

Allergy

Eczema or allergic conjunctivitis (hay fever) often seems to be associated with keratoconus. The mechanical trauma that often occurs due to forceful rubbing of itchy eyes seems to be a contributing factor to progression of keratoconus.



Topical steroids and topical antihistamines can be prescribed when there are signs of hay fever. Don't forget cold compresses, as this very simple and natural treatment is super-effective for itchy eyes. Flexible cold packs that are kept in the freezer for sporting injuries are the most effective way of delivering a cold

compress treatment. Do not forget to wrap the cold pack once in a tea towel before it is placed over the eyes, as it can be very cold and thus can irritate the surrounding skin.

Collagen disorders

The cornea is made up of many collagen fibres. It is proposed that in some patients that have keratoconus these fibres are weak and therefore stretch. When this occurs the cornea can weaken and deform. This in turn will cause the vision to blur and in many cases glasses cannot correct the vision.

Some patients with keratoconus also have floppy eye lid syndrome, sleep apnea and occasionally even heart valve conditions. These conditions are associated with collagen disorders. Do all patients with keratoconus have these associated conditions? NO, THEY DO NOT. The take home message though is they need to be checked for and managed appropriately if they co-exist.

Genetic factors

The average patient that sees us for keratoconus will not know of another family member with keratoconus.

However, recalling family history is not accurate. Studies of keratoconus have shown a strong hereditary link. Only 8% of patients with keratoconus are aware of another family member with the disease, yet up to 50% of family members will in fact have a very mild, subclinical form of keratoconus, which can only be diagnosed with very sophisticated technology and does not affect the individual on a day-to-day basis.

Up to 50% of family members will in fact have a very mild, subclinical form of keratoconus



Poor contact lens fit

Properly-fitting hard contact lenses provide the best vision for keratoconus sufferers. What is unfortunate though, is that progression of keratoconus also seems to be associated with their use. This is ironic and counterintuitive when we all know that contact lenses are the best vision solution. It is quite clear in my mind why this bizarre association exists. The reason is that too many keratoconus patients have been fitted with inappropriate, flat-fitting contact lens designs.

Keratoconus diagnosis

Keratoconus is often asymmetric, with one eye significantly more affected than the other. It is not unusual in milder cases that a misdiagnosis of amblyopia (lazy eye) occurs. If the other eye becomes visually affected then a more thorough investigation is likely to occur. I am aware of many patients that have been diagnosed later in life but originally have been mistaken as having a lazy eye. They have then been allowed to go through life with no binocular vision and all the associated issues that can occur. Today this should never happen as we have at our disposal not only proven, highly sensitive measuring technology, but also an effective procedure called collagen cross-linking that can nip keratoconus in the bud.

This makes it more important than ever to diagnose the keratoconus patient as early as possible. This procedure uses riboflavin and UV light to stop progression or at least slow it down significantly. It is especially important if the patient is under the age of 25 years of age, when progression is most likely. Diagnosis of moderate-to-severe disease is relatively simple – especially if the condition is affecting the vision bilaterally. Milder cases can be more difficult to pick up.

With the introduction of collagen crosslinking a number of years ago in Australia, it has become more important than ever to diagnose the keratoconus patient as early as possible.

Diagnostic tests for keratoconus

Corneal shape (topography)

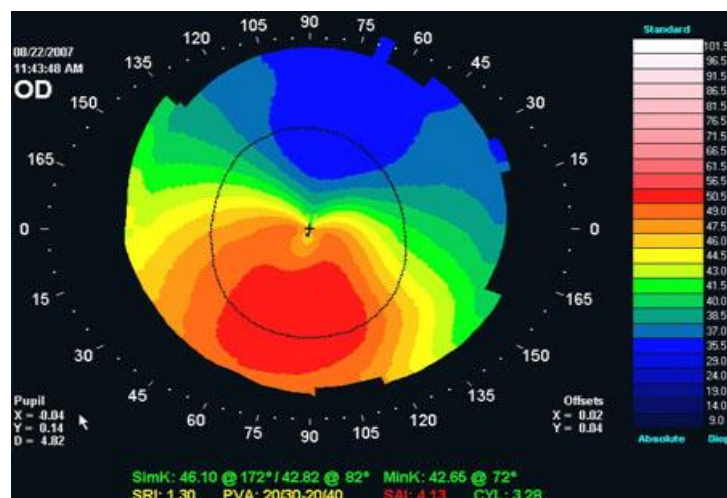
Corneal topography is the single most important tool, not only to assist in diagnosis, but to accurately monitor for progression and to assist in complex contact lens fittings. A scan of your cornea will instantly show the characteristic hallmark appearance of keratoconus (*see right*).

Corneal thickness

Even earlier diagnosis can be achieved through repeated corneal thickness measurements, which pick up subtle corneal thinning before any shape-change occurs.

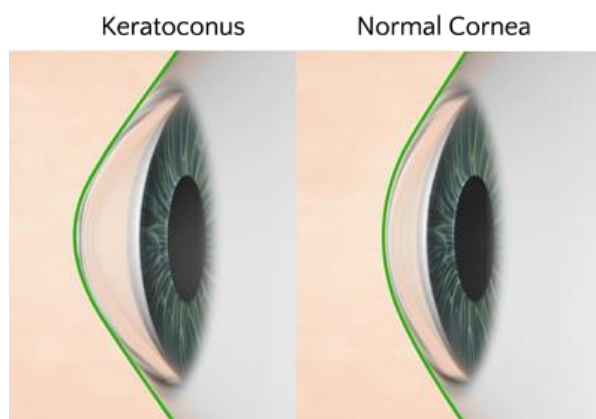
Changes to your glasses prescription

Other signs of keratoconus that can assist diagnosis include several prescription changes in a short period of time or irregular astigmatism.



Keratoconus management

Once diagnosis is confirmed, the key issue becomes management in a way that will maximise the patient's vision and, most importantly, quality of life. Typically keratoconus can have profound implications for visual quality, where spectacles can no longer provide adequate vision for everyday life.

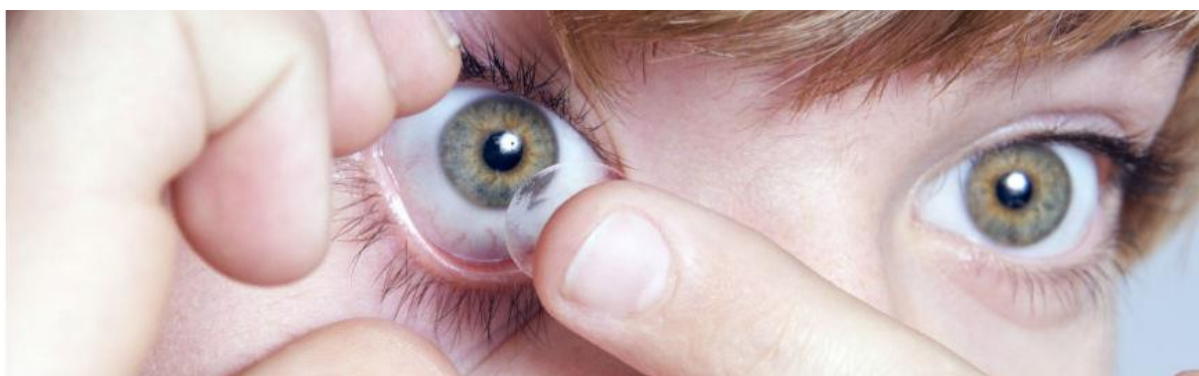

Spectacle management

Glasses may be adequate to provide functional vision in the very early stages of keratoconus but with even minimal progression of the disease, spectacle correction is inadequate to address the increasingly irregular astigmatism.

Contact lenses and keratoconus

Achieving a healthy, comfortable contact lens fit with hard contact lenses (also called RGP lenses) is the mainstay of keratoconus treatment. The fact is, most keratoconus sufferers can successfully wear contact lenses and avoid corneal graft. But the trouble is, these are not straight-forward eyes to fit with contact lenses. The average optometrist encounters a few keratoconus patients per year and doesn't build up the experience and expertise to fit them properly, especially more advanced cases. The Eye Practice sees several new keratoconus patients every week, and I have been fitting these patients for decades now. Unfortunately we see many patients who have been wearing poorly-fitting contact lenses,



which can cause a lot of discomfort as well as progression of their keratoconus. Our practice often succeeds where others have failed.

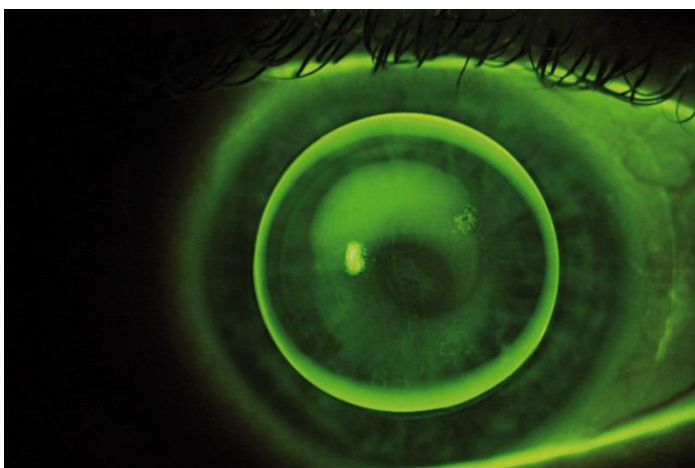
My colleagues now send me their keratoconus patients for contact lens fitting because they know they are doing the right thing by the patient. The trick is getting the right contact lens fit – that is, comfortable for the patient and gentle on the cornea.

There is nothing worse for keratoconus than a poor contact lens fit.

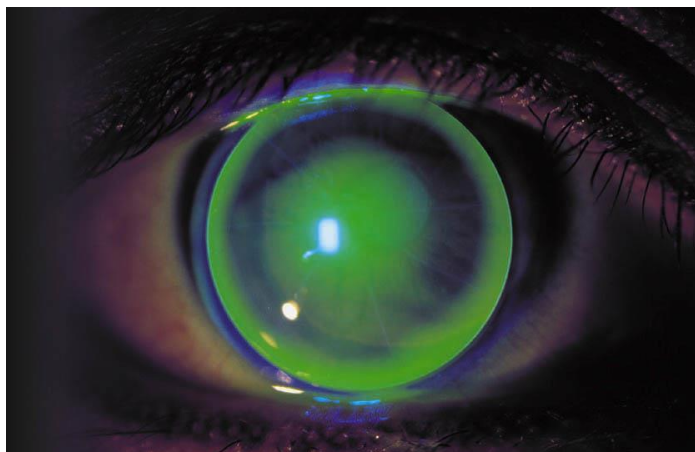
There is nothing worse for keratoconus than a poor contact lens fit. The contact lens will rub on the fragile centre of your cornea, just where it is already thinnest and it is not unusual to see patients with scars in the very centre of their corneas from a poor contact lens fit. Poor contact lens fit is one of the things that can aggravate keratoconus and cause it to progress.

Ensure you get the best contact lens fit

I mentioned that poorly-fitting (too flat) contact lenses were associated with progression of keratoconus. These lenses rub on the centre of the very fragile keratoconic cornea, which in turn breaks down the epithelium and basement membrane. This in turn will ultimately cause irreversible corneal scarring. Just like eye rubbing is associated with progression, so are flat-fitting contact lenses.



This contact lens feels comfortable, but is pressing on the thin, fragile centre of this keratoconus patient's cornea. The fluorescein dye shows the tear layer, which is absent in the centre, just where the patient needs it most to prevent the contact lens rubbing on the centre of the cornea and causing progression of the disease.



In contrast, this contact lens is vaulting the centre of this keratoconus patient's cornea. The fluorescein dye shows a pool of tears which acts like a cushion to protect the cornea from rubbing.

For the best chance of a good visual outcome, flat-fitting lenses must be avoided. If your eye care practitioner is not highly experienced in fitting the special contact lens designs required for successful contact lens wear, ensuring there is absolutely no rubbing on the centre of your cornea, it is in your best interest to be referred to a keratoconic contact lens specialist. You can do far more harm than good in the hands of an inexperienced practitioner.

Types of contact lenses for keratoconus

Mild cases of keratoconus can often be treated successfully using regular soft contact lenses or standard rigid gas permeable (RGP) designs. This is because in mild disease, the cornea has not begun to bulge significantly.

Small diameter RGPs

Typically the first lens I try is a small diameter (approx. 9mm) keratoconus design RGP contact lens. By choosing this small diameter RGP as a starting point, approximately 60% of keratoconic corneas can be successfully fitted in the long term. What is critical is that your optometrist has multiple trial sets at their disposal. No two keratoconus corneas are alike. So that leaves the 40%... This is where things can get tough. What do we go to next, if the small diameter RGPs fail?

Larger diameter RGPs

Larger lenses up to 11mm in diameter are often useful if stability cannot be achieved or if centration is poor with the smaller diameter lenses.

Piggy backs

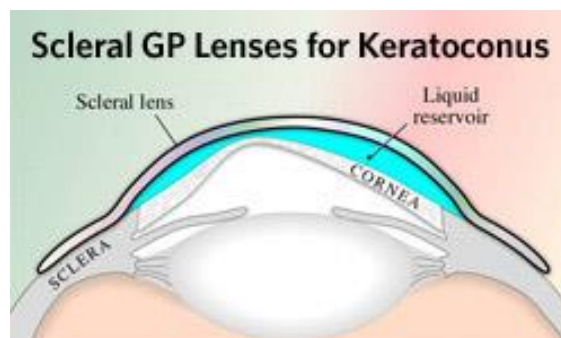At this stage a very simple option is to try and piggyback the RGP lens you already have onto a soft lens. Usually the primary reason RGPs fail is because they are too uncomfortable. Occasionally, even in the best hands, the patient is just too sensitive. Piggybacking the RGP on a soft daily disposable can be the difference. That is assuming the soft lens can drape the cornea successfully. By introducing a piggyback system with an RGP lens, success can increase by up to another 20%.

Hybrids

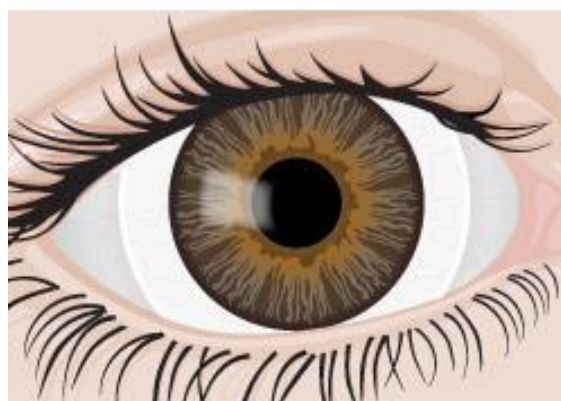Unfortunately if the keratoconus is beyond moderate, we will require other options, which can include hybrid lenses. These have a rigid centre with a soft skirt. They have a long history but were never very successful due to lack of oxygen transmission. A number of years ago, a new generation hybrid lens was released. This design definitely has a big role to play once RGP lenses fail. Hybrid lenses are also great options when any form of dynamic sport is involved. They just do not fall out.

Sclerals

Moving on from there we also have scleral contact lenses. These designs have made a resurgence amongst contact lens specialists as they are able to vault the very fragile advanced keratoconic cornea. Even very advanced keratoconus can be fitted successfully.



Large-diameter scleral and semi-scleral GP lenses rest on the sclera and vault over the misshapen cornea in keratoconus.



Cutting down on eye-rubbing

At *The Eye Practice*, when we diagnose keratoconus, one of the first things we do is tackle eye-rubbing. Keratoconus is often seen in people who also suffer from atopic conditions such as hay-fever, allergies, eczema, asthma etc. They are commonly chronic eye-rubbers and unfortunately that is one of the worst things a keratoconus sufferer can do, as eye-rubbing hastens the progression of the disease. Rubbing your eyes is bad for you. We take eye rubbing very seriously!

If you must rub, don't rub your cornea

Patients often say, Doctor, you don't understand; when I rub my eyes it just feels so GOOD... It's hard to argue with this, so once we've given the lecture on the dangers of eye-rubbing, we try to give them some strategies for breaking the habit. If you find the eye-rubbing sensation soothing, try rubbing around the eyes instead. Touch your index fingers to your thumbs to make a circle and allow this to rest around the eye, with no pressure on the eye itself. Then you can rotate your hands around the eyes, bearing on the cheekbones and eyebrows. Many patients find this brings relief from tired eyes, as it gently massages the muscles around the

eyes. Alternatively, try rubbing somewhere else. A good rub of the earlobes feels surprisingly good too!



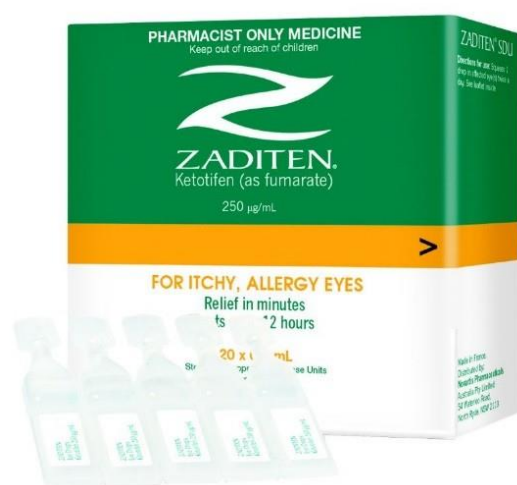Sort out the itch

The main reason for eye-rubbing is itchy eyes. And with good reason. Keratoconus sufferers are much more likely to suffer from seasonal allergies than the rest of us. Stamping out the itch is one of the best things we can do for our patients. Anti-histamines and mast-cell stabilisers are available in eye drops, which are used twice a day to combat allergic conjunctivitis. Our two favourites here are Patanol (which requires prescription) and Zaditen preservative-free ampules that can be purchased over the counter from your local pharmacy.



We sometimes recommend oral antihistamines to get to itch from the inside out. Be on the watch out for dry eyes, when using oral antihistamines. If you are wearing contact lenses and you notice your eyes become dry after taking oral antihistamines, it is best to stop the medication and seek our advice. In severe cases, the best option may be a short course of

topical steroid drops to really nail that inflammation and itching. At *The Eye Practice* we use a compounding pharmacy to make up preservative-free eye drops, so you can relax in the knowledge that your eye drops are not doing more harm than good.



Cool it down

Sometimes the best treatment is also the least invasive, and one of the best treatments for itchy eyes is simply a cold pack applied to the closed eyes. One of those gel eye-masks available from the pharmacy is perfect; just freeze it and then pop it on the eyes as you relax. Cold helps switch off the body's inflammation response, which is exactly the effect we're after.

Cold helps switch off the body's inflammation response

More about eye-rubbing and keratoconus

Eye-rubbing has been shown to aggravate keratoconus and cause progression of the disease. If we can stamp out eye-rubbing, we hope to slow down the progression sooner rather than later. Tackling itchy eyes is also of huge benefit in terms of contact lens wear. Rubbing your eyes with a hard contact lens (RGP) in place is a no-no and can lead to corneal thinning and scarring as the lens rubs against the fragile centre of your cornea.

One of the most common times to want to rub your eyes is straight after removing your contact lenses at the end of the day. Many of our patients complain that the itch at this stage is nearly unbearable. If you are already using a preservative-free antihistamine or mast-cell stabiliser twice a day, make sure you have your cold pack ready to use as soon as you remove your lenses. It will be bliss! Comfortable, itch-free eyes lead to successful contact lens wear and nothing makes us happier than seeing our keratoconic patients comfortable in contact lenses and avoiding a corneal graft.



New treatments for keratoconus

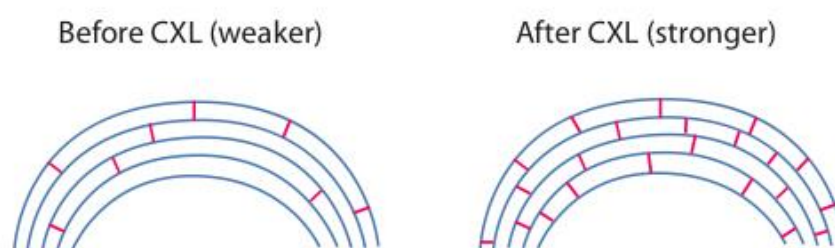
If you've got keratoconus and think that a corneal graft is your only option, read on. Corneal graft is often presented as the ultimate treatment for keratoconus, but in reality it should be your last resort. A comfortable contact lens fit is the mainstay of keratoconus treatment but there are some new procedures which can greatly improve your outlook without having to resort to a graft.

Corneal graft is often presented as the ultimate treatment for keratoconus, but in reality it should be your last resort.

What is corneal collagen cross-linking?

Keratoconus is a disease of the cornea, or front surface of your eye. The cornea becomes weaker and thinner and starts to lose shape and droop. The majority of your cornea is made up of collagen fibres arranged in very orderly rows. It is useful to think of them like pipes in a builder's yard – neatly stacked in row upon row. Their perfect orderliness is the exact reason the cornea is transparent: light waves can literally weave their way through the collagen fibres. Now imagine that the pipes can slide around a little, and don't stay in their neat rows. This is similar to what happens in your cornea in keratoconus. If we can bind those collagen fibres together somehow, we have a much stronger cornea and progression of the disease is halted. Collagen fibres naturally start to bind together – or cross-link – as we age. Younger eyes

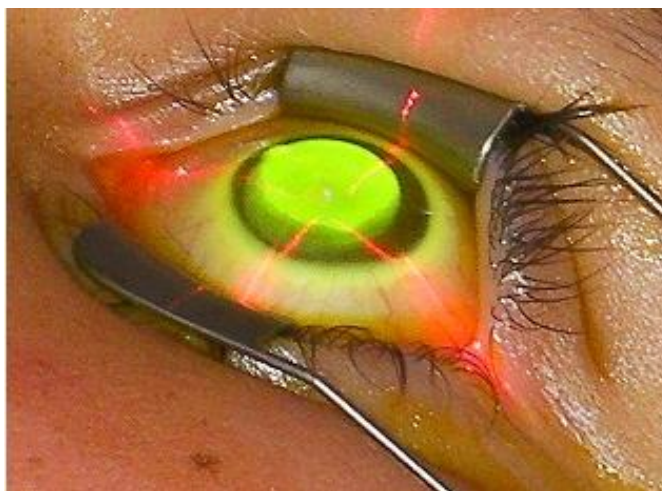
have few links between the fibres, whereas more mature eyes naturally have this stronger structure.



Corneal layers (blue) and the collagen-cross links (orange) before and after CXL.

How does corneal collagen cross-linking work?

Using an application of riboflavin (Vitamin B2) eye drops followed by treatment with ultraviolet (UVA) light, the cornea develops bonds between its fibres and your keratoconus is halted in its tracks. It doesn't fix the problem or reverse the damage; it simply prevents it from getting any worse. For this reason, collage cross linking is suited to keratoconus sufferers in the teens and twenties – i.e. when the disease is still progressing. It is pointless having corneal collagen cross-linking if your keratoconus has already stabilised, which it typically does by your late 20s / early 30s. The earlier you can get corneal collagen cross-linking, the better, so we promptly refer our patients for this procedure as soon as we diagnose them with progressive disease.



What are intra-corneal ring segments?

Intra-corneal ring segments (also known as Intacs or kerarings) are small Perspex devices which are placed inside your cornea in a minimally-invasive procedure. A special laser is used to create a channel within your cornea and the ring segment is placed inside the channel through a tiny keyhole entry point. The rings provide support (not unlike the underwire in a brassiere!) and provide a better shape to the cornea. When successful, they reduce astigmatism and improve vision and help keep patients away from corneal grafts for longer. They are useful for patients who cannot achieve a satisfactory contact lens fit but want to steer clear of a corneal graft for as long as they can.



Seeing an expert guarantees a better outcome...

Both corneal collagen cross linking and Intra-corneal ring segment procedures are performed by a corneal surgeon in a day-surgery facility. We are fortunate to work closely with some of the best corneal surgeons in the country and part of our keratoconus management program is to provide referrals for these procedures where appropriate.

If all else fails, there is no doubt that a corneal graft is a sight-saving procedure and can help keep many advanced keratoconus sufferers seeing well enough to live a full life. But a corneal graft should only be considered when an experienced, expert keratoconus contact lens specialist has failed to achieve a healthy, comfortable fit. Happy contact lens wear is a far better outcome than a corneal graft and well-fitting contact lenses will provide far better vision than can be achieved with cross-linking, intra-corneal rings or a corneal graft.

Happy contact lens wear is a far better outcome than a corneal graft.



What's in the pipeline?

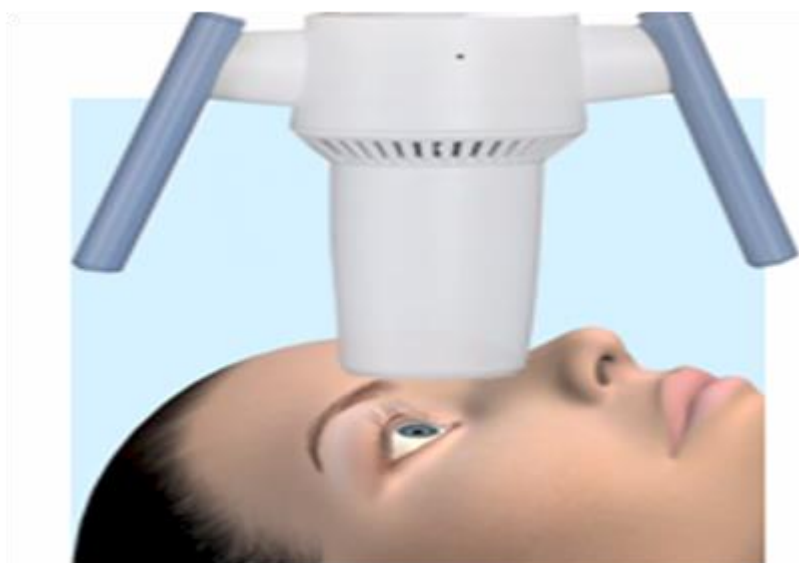Collagen cross linking combined with laser resurfacing

Very new is a procedure which combines collagen crosslinking with topographically-guided laser resurfacing. At this stage it is still experimental and only indicated in patients that have definitely failed in contact lenses and whose keratoconus is relatively mild to moderate. We believe, until this procedure has been established in the peer-reviewed literature to give safe and accurate outcomes, that mild to moderate keratoconus sufferers who can't wear contact lenses are better off in glasses. Because the already thin cornea is thinned even more by the laser reshaping, this technique could be a fast-track to a corneal transplant. However, it may have a role to play as a last resort to try and avoid a corneal graft in a patient who has failed in contact lenses.

Keraflex

Keraflex is a new procedure for the treatment of keratoconus which is still under investigation. In this procedure, a single, low energy microwave pulse is used to shrink collagen fibres and thus flatten the cornea without removing any tissue – which is usually high risk in keratoconus. The treatment takes less than a second and is combined with an accelerated (less than three minutes) version of collagen cross linking to improve the stability of the cornea. This

Keraflex may ultimately help keratoconus sufferers with no alternative therapeutic options to avoid or at least delay progression to corneal transplant



procedure is still undergoing trials but it is believed that it may ultimately help keratoconus sufferers with no alternative therapeutic options to avoid or at least delay progression to corneal transplant.

Corneal grafts and keratoconus

No keratoconus discussion would be complete without a mention of corneal transplantation (or graft). For years I have been following the survival rates of corneal transplants via a document published every year by the Australian Corneal Graft Registry. It very clearly shows that 50% of corneal transplants will fail within fifteen years. It is also clear that subsequent transplants will very likely survive less due to a primed immune system.

Hypothetically, if a twenty-year-old patient has a transplant and this transplant is rejected at fifteen years, they will only be thirty-five. By the time they have had a fourth transplant it is unlikely to survive more than two years.

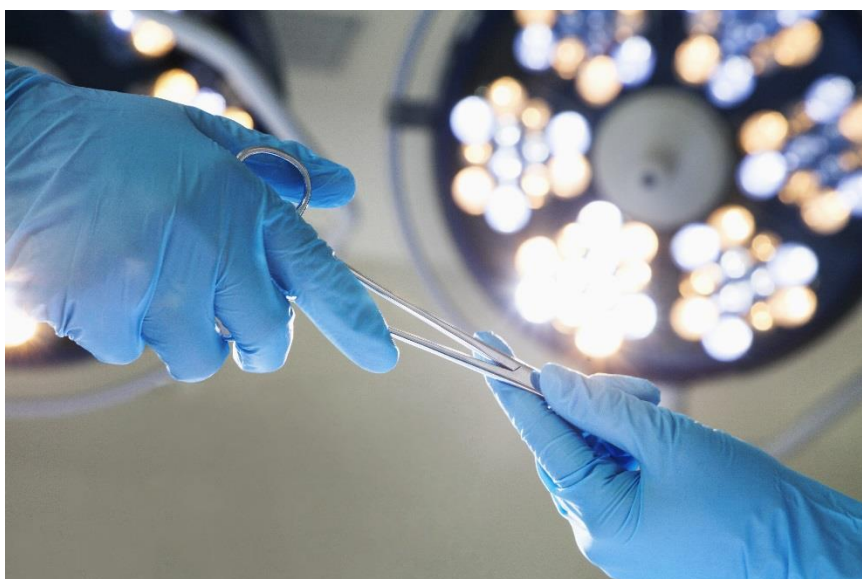
Corneal graft is often presented as the ultimate treatment for keratoconus, but in reality it should be your last resort.

Corneal graft is often presented as the ultimate treatment for keratoconus, but in reality it should be your last resort. At *The Eye Practice*, it never ceases to amaze me how keen our keratoconus patients are to consider a corneal graft. They seem to believe it will be a quick fix for their eye disease but there are some things about corneal grafts that they just may not have considered.

Here are some of the most common myths about corneal grafts:

Myth 1. A corneal graft is the ultimate treatment for keratoconus...

This is a common misconception among keratoconus sufferers and even many inexperienced eye practitioners. In fact, properly fitting contact lenses are the mainstay of keratoconus treatment. This is possible in most cases. If your optometrist has shied away from contact lenses or has referred you directly to a corneal surgeon to



discuss a graft, then you're not alone. We commonly see patients who have been passed around from one optometrist or corneal surgeon to another, without ever seeing an expert contact lens fitter, who specialises in keratoconus.

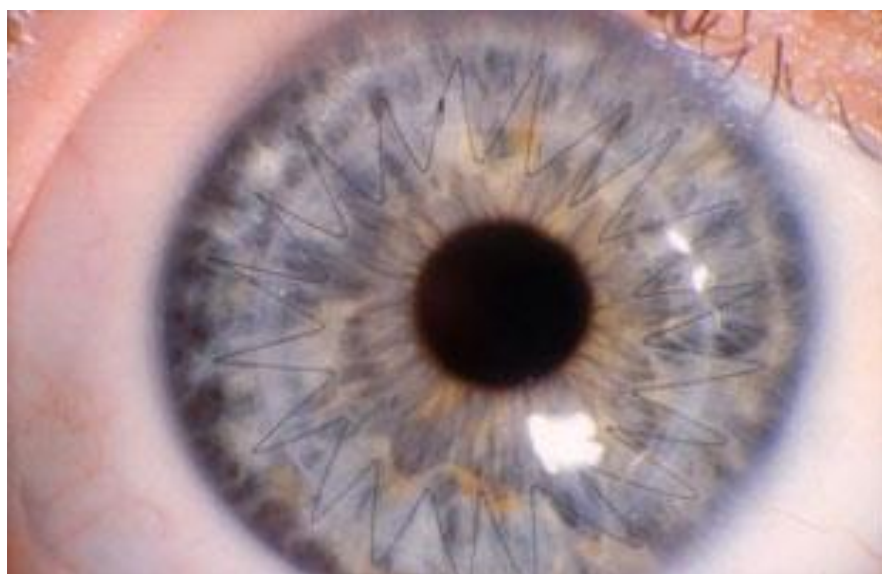
There are lots of different contact lens designs to choose from: apart from the most commonly fitted hard lenses there are also hybrid lenses (which have a hard centre with a comfortable soft 'skirt' at the edge), scleral lenses (which vault the cornea and bear on the less sensitive white of the eye) and even piggy-back lenses (where a hard lens sits on top of a soft lens to improve comfort). Managing any underlying allergy or inflammation can also lead to successful contact lens wear and this is another area of focus at our practice.

In terms of achieving clear vision, comfortable, safe, hard contact lens wear is the best possible way to manage your keratoconus.

Myth 2. It will be just like it was before I developed keratoconus...

Unfortunately this is not the case. Some keratoconus sufferers have the belief that if only they could have a corneal graft, all their problems would disappear. They would be back to where they started before they ever developed keratoconus. But this is far from the truth. There is no doubt that a graft is a sight-saving procedure where contact lenses have failed – even when fitted by a contact lens expert. Even here at *The Eye Practice*, where we see keratoconus day in, day out, there sometimes comes a time when we have exhausted all options and a graft is the only way to restore vision to a level that provides reasonable quality of life.

Once you have a graft, the road to recovery is a long one. The suture remains in your eye



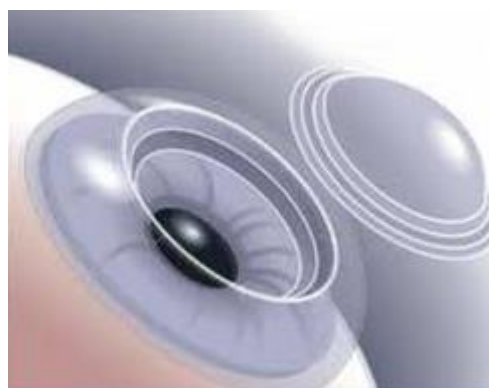
for a year, before it is removed. Vision is usually better than before the graft, often much better, but don't expect 20-20 vision. Most patients are delighted if they can achieve adequate vision to legally drive after their graft surgery.

Myth 3. Once I get the graft, that's it for life...

One of the problems with a graft is that it doesn't last forever. You can expect at least ten years from a successful graft surgery, but by about fifteen years, 50% of grafts have failed. The longer you can postpone a graft the better, and better still if you can avoid one completely. Don't forget, a corneal graft is a transplant. Tissue comes from a donor eye, and even with the best tissue-matching there is always the possibility of rejection by your immune system. For this reason, you may be on steroid eye drops for a long time. This has implications for the long term health of your eyes.

You can expect at least ten years from a successful graft surgery, but by about fifteen years, 50% of grafts have failed.

Donor corneas are given to those most in need, so there may be a considerable wait for a suitable cornea to become available. For all of these reasons, it is always in your interest to exhaust the possibilities of contact lenses before talking to a corneal surgeon about a graft.



Types of corneal graft

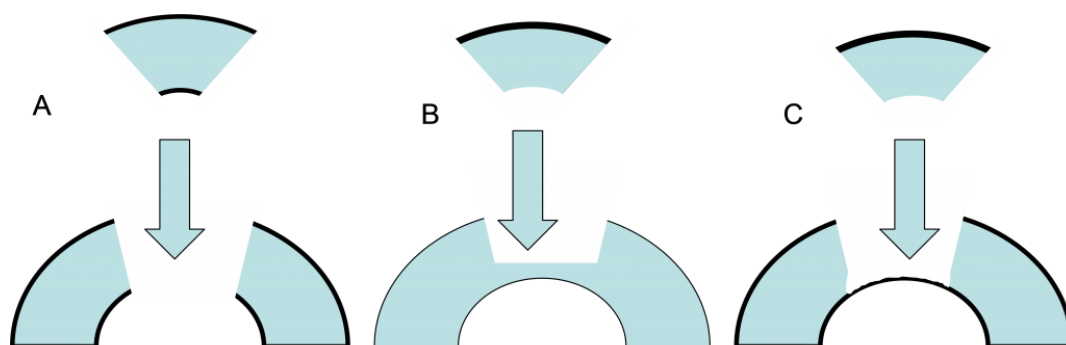
Corneal graft or transplantation (also called keratoplasty) involves the removal of a diseased section of your cornea and the replacement with a section of donor cornea.

Full thickness graft (A)

This is where the section of cornea that is replaced consists of all the layers. It is the most commonly performed type of corneal graft.

Partial thickness (lamellar) graft (B and C)

Partial thickness grafts are becoming more common as techniques improve and they have some advantages over full-thickness grafts.



Case study 1

Joe is a 17-year-old male doing his HSC, and was referred to us by his local optometrist for specialist contact lens fitting. Glasses could not allow Joe to achieve the vision required for his driver's license, and he was also suffering from headaches and sore, tired eyes. Joe was nervous of going outdoors at night as the flaring and multiple ghost-images around lights were debilitating. His mother, who accompanied Joe for his consultation, was worried he was becoming antisocial.

On examination, Joe's keratoconus was mild to moderate and, according to his referral, his condition seemed fairly stable. As there was a small chance of his keratoconus not progressing, we didn't recommend collagen crosslinking just yet.

We successfully fitted Joe's eyes with RGP contact lenses, which achieved 6/6 (or 20/20) vision in each eye. After a week of building up his wearing time, Joe was able to tolerate his lenses all day. Joe returned for routine aftercare two weeks later and we made some minor adjustments to the lens fit, to guarantee no contact lens irritation.

3 months later, we reviewed Joe and his vision was unchanged wearing lenses all day every day. We reviewed him again after his HSC and there was evidence of slight progression in the right eye. At this stage Joe was referred for collagen

crosslinking for his right eye. This was successfully performed and Joe returned to us for contact lens review and progression assessment, especially

This is not a set-and-forget contact lens fitting.

for the left eye that has had no procedure. **It is vitally important that keratoconus patients wearing contact lenses have regular reviews.** This is not a set-and-forget contact lens fitting. The disease is very dynamic, in these younger eyes in particular, and a contact lens which seems to fit well, with no rubbing on the cornea can quickly turn to a poorly-fitting lens with the potential to cause permanent scarring to the cornea and necessitate a corneal transplant.

We reviewed Joe every 6 months for 3 years and there were no further changes. His contact lenses needed replacing at the 2 year point due to normal wear and tear. His old lenses were kept as a spare pair in case of loss or breakage. Often it is advisable to get another set of lenses as soon as possible, as it typically it takes two weeks to get another set.



7 Things you should know about keratoconus

Keratoconus is a disease of the front surface of the eye that often is visually debilitating. It affects only 1/2000 of the population, so in Australia it is estimated that at least 10,000 people suffer with this condition. Many struggle to function in everyday life due to inappropriate treatment options or advice.

An important point to consider is that most eye care practitioners see about 2,000 eye patients per year, so on average they will only come across one keratoconic patient per year. It doesn't matter how smart you are; if you don't involve yourself frequently with an activity you will never develop the skill to deal with it effectively and efficiently. There is no substitute for experience.

Because there is a lack of experience in managing keratoconus, often a patient with the disease will be steered in an

Most eye care practitioners...will only come across one keratoconic patient per year.

inappropriate direction. Fortunately, you can be different! What follows are the seven vital issues in keratoconus that, if not understood, can lead to significant problems, inconvenience, grief and emotional distress. When you understand and apply these important principles you can be at ease with this frustrating condition.

1. Keratoconus is not a blinding condition

It amazes me that most of the patients I see fear that they will eventually go blind. This belief occurs simply because they have seen their vision get worse and worse so they fear that the eye condition will continue to degrade to the point that nothing can be done to recover the vision.

Some people have seen a number of eye care practitioners over time and no one has been able to fit them with contact lenses or glasses and they are too scared to



pursue corneal transplant surgery. They then try to function with poor vision and believe it is only a matter of time before they will see nothing at all. The reality is that no one goes blind from keratoconus. There are currently several options before corneal transplantation might be required, including:

1. Glasses
2. Soft contact lenses
3. Rigid gas permeable contact lenses (when fitted properly this is the most successful option)
4. Rigid gas permeable lenses piggybacked on soft disposable contact lenses
5. Mini-scleral contact lenses
6. Intra-corneal ring segments with corneal collagen cross linking.
7. Re-prescribing glasses, soft contact lenses or rigid gas permeable contact lenses after intra-corneal ring segments have been installed in your cornea

If corneal transplantation is finally required, its success rate is greater than 95% when done by an expert corneal surgeon. Please note that glasses or contact lenses are normally required after surgery, but visual quality is normally good to very good once the eye has healed. It is important to understand vision correction is still required in most cases. Somewhere along the line we always get reasonable vision.

2. Keratoconus does not progress forever

Typically when I see a patient with keratoconus for the first time, they have been referred by another optometrist or ophthalmologist (eye surgeon). They are usually in their teens and they are accompanied by their parents. Keratoconus usually begins slowly or aggressively as a teenager during puberty. In keratoconus, the front window of the eye (the cornea) becomes thinner and eventually destabilizes and becomes irregular in shape, which causes a deterioration in the vision.

When I see a teenager accompanied by their parents I normally have a long and careful discussion, as everyone is stressed and upset.

The typical keratoconus patient assumes that the condition will continue to progress forever. When I see a teenager accompanied by their parents I normally have a long and careful discussion, as everyone is stressed and upset.

The good news for most people is that keratoconus usually stabilizes quite nicely after twenty-five years of age except when:

1. Poorly fitted contact lenses are used
2. The affected person regularly and aggressively rubs their eyes.

Having read many articles on keratoconus in the literature and on the internet it is common to read that keratoconus progresses through to forty years of age. This has not been my experience when lenses are fitted properly and the affected person and his/her family have careful counselling about the potential damage that is done by eye rubbing.

The moral to the story then:

“I promise to fit the lenses properly as long as you significantly decrease eye rubbing.”

3. Significantly decreasing eye rubbing is essential!

People that have keratoconus often also have allergies. Hay fever, skin allergies, and asthma are common. With these conditions come itchy eyes. Another group of people that has keratoconus does not seem to have allergies but they do have a habit of eye-rubbing. Aggressively rubbing eyes can cause or progress keratoconus. Therefore it is very important to have strategies to decrease the urge to rub.

It is theorised that rubbing eyes that are predisposed to keratoconus traumatises the cornea causing it to thin and become distorted in shape. This causes a distortion in vision that often cannot be corrected with glasses.

One thing is to know that eye rubbing is a problem and another is putting a halt to it.

People that get itchy eyes will tell you that it drives them mad and once they start they cannot stop until their eyes are red raw. It is this vicious cycle that can progress keratoconus. (See page 11 for strategies to reduce eye-rubbing).

Decreasing eye rubbing cannot be overstated. You need to stop and you need to stop now.

4. Not all contact lens solutions are the same

Impeccable contact lens hygiene is critical to the ongoing success of contact lens wear and consequently good vision. It is obvious that keeping the contact lenses clean is important to maintain good eye health, but did you know that the solutions themselves often cause toxic or allergic reactions, which can make contact lens wear from uncomfortable to unbearable?

Preservatives in contact lens solutions can make eyes go red, feel gritty and itchy.

Contact lens solutions are preserved so that they remain sterile. Preservatives kill live bacterial cells but the eye is also made up of cells, which can be affected by these same preservatives.

Preservatives in contact lens solutions can make eyes go red, feel gritty and itchy. In cases like this I recommend a quick rinse with an unpreserved lubricant before inserting the lens into the eye. By rinsing the lens with an unpreserved solution before insertion, this dilutes most of the preservatives off the lens after the overnight disinfection process and therefore they do not then have the opportunity to cause an adverse reaction.

Remember what we said before. Many patients with keratoconus suffer with allergies and are therefore more sensitive to irritants. Unfortunately the very solutions that protect our eyes from infections can also cause an allergic or toxic reaction. The procedure as described before though is not too difficult and often creates significant improvement in comfort, leading to successful contact lens wear.

5. One-step cleaning solutions are not a good idea

When I start a contact lens patient on a cleaning system I try to keep it simple, but not too simple! Many solutions today are promoted as “one step” and “no rub”. For rigid gas permeable lenses I believe these types of solutions do not make any sense. These types of lenses normally have a life expectancy of at least twelve months. It is important to rub them with a detergent-based cleaner. The cleaner then needs to be thoroughly rinsed off with saline and then the lenses need to be soaked in a disinfecting solution overnight. Often a protein-removing solution also needs to be added to keep the lenses squeaky clean.



Unfortunately many patients are lured into the easier “one step” “no rub” solutions, innocently thinking that their lenses will be cleaned properly. This is not the case and will significantly shorten lens life and cause eye irritations in many patients. It is a bit like saying to wash your hair only with conditioner and never use a shampoo.

6. Your optometrist should professionally polish your contact lenses

This is very important when keratoconic contact lenses are involved. Your practitioner should be pre-booking you at least every six to twelve months. Remember this: most people that have keratoconus are nearly 100% reliant on their rigid gas permeable contact lenses. Often glasses do not work very well and consequently contact lenses are worn during all waking hours, seven days per week.

Professionally polishing rigid gas permeable lenses using aluminium oxide is an often forgotten but extremely effective troubleshooting tactic. Despite your best efforts in cleaning, rigid gas permeable contact lenses can either deposit with natural tear secretions or lose their wet-ability. Both of these circumstances can cause significant discomfort and fluctuating visual quality.

Once the lenses have reached this state there are really only two options:

1. Throw the lenses away and buy a new pair
2. Professionally polish the lenses and resurrect them.

By polishing the lenses, their surfaces are returned to their original pristine condition and you can once again wear the lenses comfortably.

Polishing rigid gas permeable contact lenses is a specialised activity. If not done properly the surface of the contact lenses can be burnt and the lenses are then ruined. I also do not recommend polishing the lenses more than twice, as the lenses slowly lose their durability and can split in the process. It is therefore imperative that you have a spare pair of lenses before offering your current lenses for polishing. Remember it can take up to ten days to manufacture another set of lenses, so having a spare pair is always a great insurance policy.

7. Keratoconus specialists are far and few between

Earlier I mentioned that the prevalence of keratoconus in the general population is only 1/2000. In a country the size of Australia there are therefore only about 10,000 people that have clinically significant keratoconus.

There are approximately 3,000 optometrists in Australia so if patients with keratoconus were evenly distributed every

The good news is that there are a number of highly-skilled optometrists around the country that look after many keratoconus patients.

optometrist would only have three keratoconic patients to look after. No optometrist in the country could possibly develop any expertise in this area with so little practice.

The good news is that there are a number of highly-skilled optometrists around the country that look after many keratoconus patients. The bad news is that they are almost all in the capital cities of Australia, so if you live in a rural area there is a good chance you have to travel to get expert attention.

If you read this report and have or know someone with keratoconus that is having a difficult time, I invite you to contact me via email at: jim@theeyeppractice.com.au

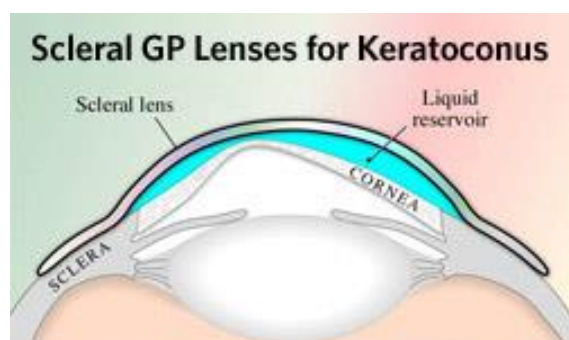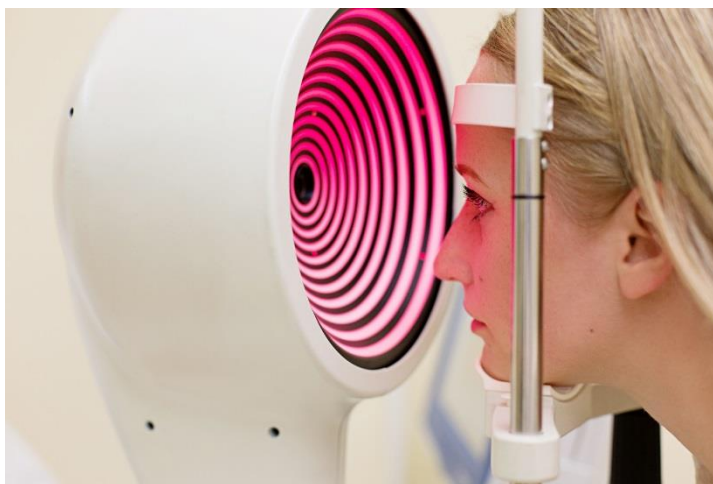If it is too difficult to see me in Sydney, I will direct you to your nearest keratoconus specialist. With the appropriate care you will get an action plan into place quickly and efficiently. In no time at all you will wonder what all the trouble was about.

Case study 2

Clare is a 20-year-old female referred by an ophthalmologist for specialist contact lens fitting prior to considering a corneal transplant.

Clare is 'successfully' wearing a small diameter RGP contact lens in her right eye, which gives her 15% less than 20/20 vision. Her left eye has never been successfully fitted, as the contact lens could never be made to stabilise and kept falling out.

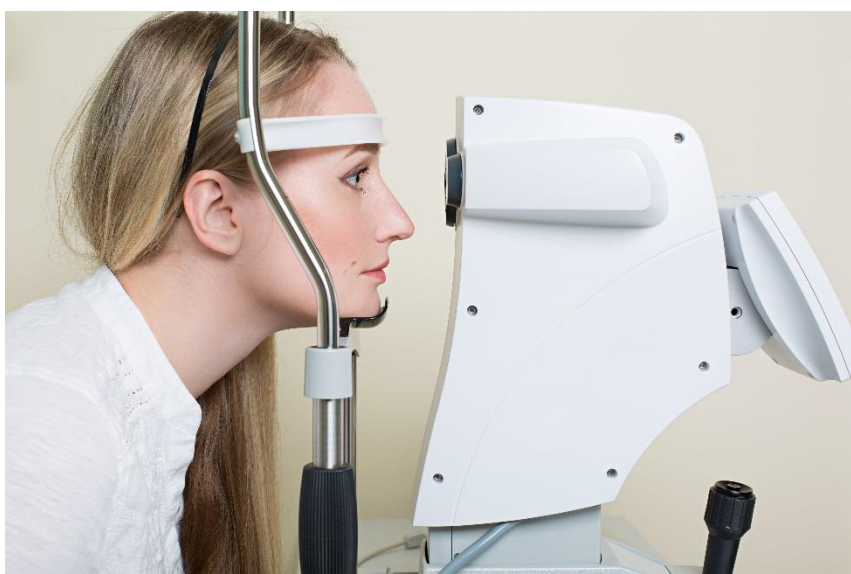This case report is quite a typical one. Even the eye that 'successfully' wears a contact lens has no long-term future as it is abrading (rubbing away) the centre (or apex) of Clare's fragile cornea and it is only a matter of time before she develops a corneal ulcer.




In many of these cases, the more difficult eye usually has moderate to advanced keratoconus and requires a more sophisticated lens fitting. Fitting with a larger diameter RGP lens, a hybrid lens or even a scleral lens are all potential solutions. (See page 10 for more on these types of lenses).

In Clare's case, her keratoconus is quite advanced in her left eye and she could only be fitted with a scleral lens. This lens places all the pressure on the insensitive sclera and does not touch the fragile apex of the keratoconic cornea.

Once this eye was fitted successfully we then moved on to the 'successful' right eye and changed the fitting to guarantee long-term safety. We were able to fine tune the vision so that Clare was 5% short of 20/20 in her right eye and 15% short of 20/20 in her left eye. Using both eyes together, Clare could achieve 20/20 vision for the first time in many years and was able to avert the need for a corneal transplant.



About the author



Dr Jim Kokkinakis is one of Australia's most experienced optometrists and is well known amongst his peers as an expert in contact lens fitting and troubleshooting. Many colleagues refer their patients to Jim's practice in the Sydney CBD. Over the past three decades he has worked alongside world-famous contact lens fitters and ophthalmic surgeons.

In 1986 Jim developed a special interest in complicated contact lens fitting and slowly but surely it became a hobby and

His commitment to excellence sets him apart

passion. He realised that to succeed in contact lenses one must have a good medical knowledge of the eye, a good understanding of the patient's lifestyle, environment and expectations, and an up-to-date approach to contact lens materials and cleaning systems. Last but not least, you have to invest in the latest technological instruments so that even the most subtle changes can be measured in visual function and eye health.

Career Highlights

- Senior lecturer and clinical supervisor at the Optometry School (UNSW)
- Co-author of *Keratoconus – A User's Manual*
- One of only 40 full members of *The International Society of Contact Lens Specialists*
- Lectured internationally on advanced contact lens fitting, dry eye treatment and computer vision syndrome.
- One of Australia's first optometrists to be qualified in Ocular Therapeutics

Dr Jim Kokkinakis specialises in the fitting and supply of the complete spectrum of contact lenses for keratoconus and has the experience and expertise to fit you. The best solution can be found for each individual patient. He will NOT stop until he has a workable solution.

Call today on 02 9290 1899 for an appointment with Dr Jim Kokkinakis
